

## Diagnostic Recommendations


ESCCAP UK & Ireland

Canine angiostrongylosis is an endemic disease in the United Kingdom with increasing numbers of diagnosed cases in dogs and other canids. It is caused by the worm *Angiostrongylus vasorum*, a nematode that resides as the adult stage in the pulmonary arteries and the right side of the heart in dogs and other carnivores (excluding cats), which can be spread to canines and foxes from mollusks and some amphibians.

First discovered in France, *A. vasorum* is sometimes referred to as a lungworm and sometimes named 'the French Heartworm' because the adult worms are located in the circulatory system and not the lungs. Since the late 1990s, there has been expanding prevalence of the disease in the UK, Scandinavia, Germany, Italy and other parts of Europe. All canines who spend time outdoors in these endemic areas are at risk of infection.

Angiostrongylosis is a crucial differential diagnosis in any dog with respiratory, coagulopathy, neurological or syncopal signs of unknown etiology. Clinical signs include coughing, dyspnea, spontaneous or uncontrolled bleeding, weight loss, vomiting, abdominal pain, lumbar pain, neurological signs and heart failure. Subclinical angiostrongylosis has also been reported. The availability of safe and effective treatments has led to more speculative treatment for *A. vasorum* without a diagnosis. Testing dogs with relevant clinical signs is important to confirm *A. vasorum* as a possible cause but also to establish if the parasite is present locally. This is vital to inform preventative advice for the parasite to other pet owners. Regular diagnostic controls or monthly anthelmintic treatments against this parasite prevent the onset of important clinical signs.

Until recently, the Baermann technique has been the gold-standard method for detecting the parasite. It has the advantage of detecting larvae from a variety of lungworm infections. However, this method can be cumbersome, time-consuming, relies on fresh faecal samples collected over several days and is limited by the intermittent shedding of the larvae in the faeces. While remaining the foundation of lungworm diagnosis it can now be used in association with more vet practice friendly, commercially available antigen tests for *A. vasorum* infection. An antigen test reliably indicates infection.



### It is time to start testing pets

The presence of high prevalence focal areas of *Angiostrongylus vasorum* across the United Kingdom means that effective diagnostic testing is required to rapidly diagnose clinically affected animals.


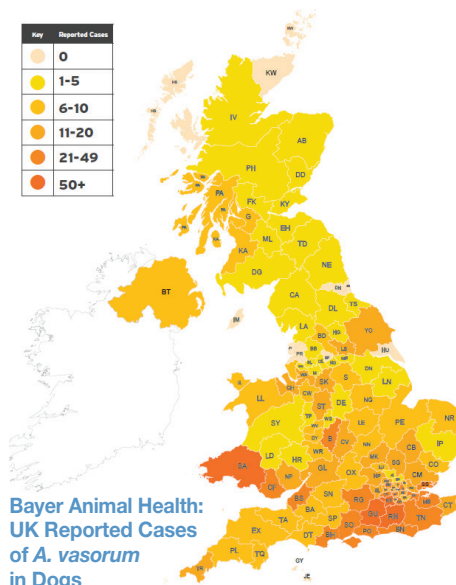
This helps inform risk-based preventative advice based on geographic incidence.

A variety of tests are available to potentially diagnose *A. vasorum* infection in dogs.

### Prevalence is growing

Studies in the United Kingdom point to an expanding prevalence in routine diagnostics. A 2015 study of Great Britain and the UK evaluated *A. vasorum* prevalence in foxes compared to an identical serological study performed in 2005. Prevalence of *A. vasorum* was 18.3% compared with 7.3% previously, and had increased significantly in most regions, for example 7.4% in the Northern UK (previously zero) and 50.8% in the south-east (previously 23.2%).<sup>1</sup>

Key	Reported Cases
White	0
Light Yellow	1-5
Yellow	6-10
Orange	11-20
Dark Orange	21-49
Red	50+



<sup>1</sup> Taylor et al., (2015), 142 (9); 1190-5

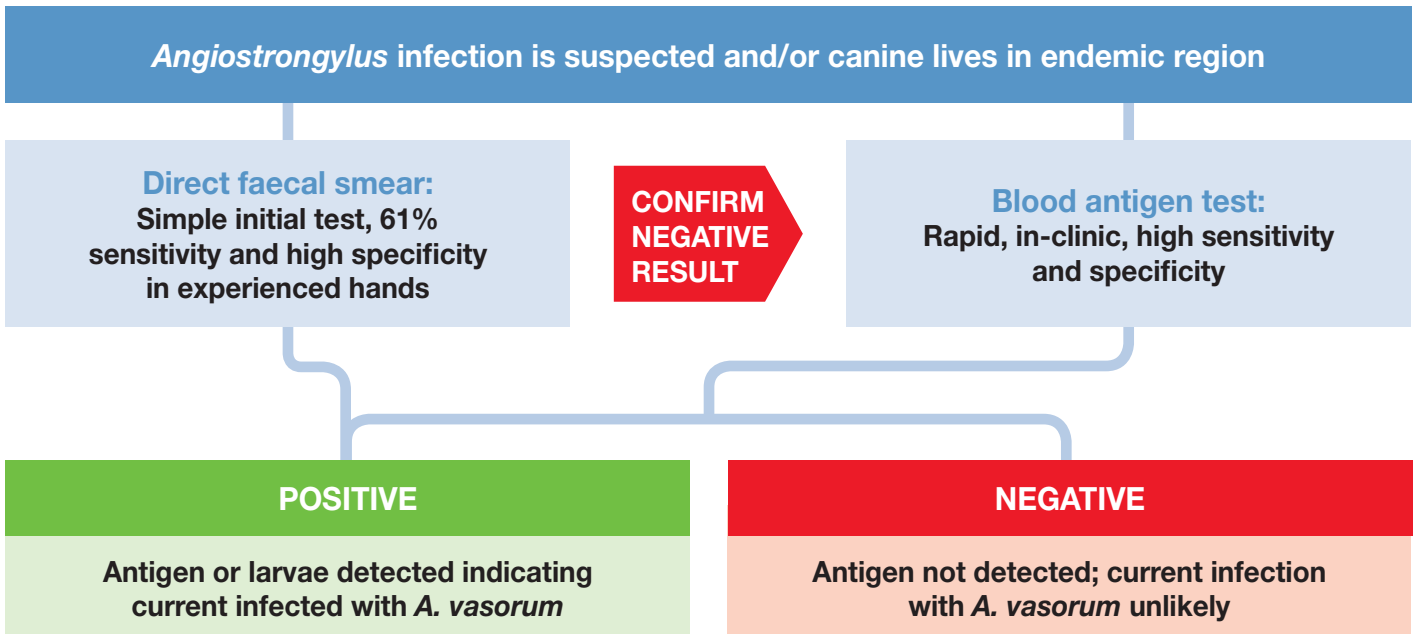
## Dogs with suspected *A. vasorum* infection

The clinical signs of Lungworm are numerous, varied and non-specific. They include:

- Cough and other respiratory signs
- Prolonged or excessive bleeding
- Neurological signs
- Lethargy, exercise intolerance, 'under the weather'

These clinical signs may be present in a range of other cardiovascular and systemic conditions and diagnostic tests for *A. vasorum* should form part of a wider diagnostic work-up for other relevant conditions in the patient. ESCCAP UK & Ireland recommends annual screening for *A. vasorum* in countries where the parasite is endemic.

*Angiostrongylus vasorum* may remain subclinical for months to years and should be considered before surgery, especially in highly endemic areas.



- Initiate treatment for angiostrongylosis with licensed macrocyclic lactone product. Consider other possible concurrent causes for clinical signs.
- Avoid surgery until the dog is free of the parasite.
- Re-infection is likely in dogs with a propensity to eat slugs and snails. Ongoing prevention therefore essential. Discuss with the pet owner.
- Re-testing is recommended approximately three weeks after starting the anthelmintic treatment(s) to check that treatment has resulted in the removal of adult worms
- Other dogs in the same household and region are at risk of infection and should be tested.

- Discuss prevention of *A. vasorum* with the pet owner.
- If *A. vasorum* is still suspected or other lungworm infections such as *Filaroides osleri* or *Crenosoma vulpis* (respiratory signs primary presentation, multiple kennel or race dogs affected etc.) then submit a faecal sample for the Baermann technique.
- For lethargy, exercise intolerance, consider cardiac and other respiratory causes.
- For prolonged or excessive bleeding, consider rodenticide intoxication, platelet concentration and function, inherited coagulopathies and others.

## ESCCAP UK & Ireland Supporters 2019

Sponsors:

Donors:

Fellowships:

