

There is a wide range of ectoparasites that can infest dogs and cats in Europe. Many ectoparasites may act as vectors for various important companion animal infections.

The following series of modular guides for veterinary practitioners gives an overview of the most important canine and feline ectoparasite species and suggests control measures in order to prevent animal and/or human infestation<sup>1</sup>.



### 3.1. Fleas:

*Ctenocephalides canis*, *Ctenocephalides felis*



### 3.2. Ticks:

*Ixodes ricinus*, *Rhipicephalus sanguineus*,  
*Dermacentor reticulatus*

### 3.3. Sucking and chewing lice:

*Linognathus setosus*, *Trichodectes canis*  
and *Felicola subrostratus*

### 3.4. Sand flies and mosquitoes

### 3.5. Mites:

- a. Demodicosis
- b. Sarcoptic mange
- c. Notoedric mange
- d. Otodectosis
- e. Cheyletiellosis (fur mite)
- f. Harvest mites
- g. Canine nasal mites



<sup>1</sup> For more information see:  
ESCCAP Guideline 03: Control of Ectoparasites in Dogs and Cats.  
ESCCAP Guideline 05: Control of Vector-Borne Diseases in Dogs and Cats.

## Diagnosis of ectoparasite infestation

**Fleas:** Low numbers of fleas may remain undetected. Close inspection and combing can detect fleas and flea dirt within the hair coat.

**Ticks:** Small larval and nymphal stages can easily be missed. Also unengorged adult stages, particularly in dogs with long fur, are often overlooked. Thus, most adult ticks are found only after they have been attached for at least two days. Also the presence of local skin reactions to tick bites can help to diagnose the infestation.

**Sucking and chewing lice:** Louse infestation can be diagnosed by close inspection and detection of adults or their eggs (nits) within the hair coat.

**Sand flies/mosquitoes:** Skin reactions such as weals on the skin of the animal may be the first sign of bites.

**Mites:** Microscopic examination of skin scrapings from affected areas of alopecia (*Demodex*, *Sarcoptes*, *Notoedres*), skin scales (*Cheyletiella*), cerumen swabs (*Otodectes*), nasal swabs (*Pneumonoisoides*) is required to identify the presence of mites.

## Preventive and control measures

**Fleas:** Animals should be groomed regularly to identify the extent of infestation. Regular treatment with appropriate insecticides and daily vacuuming, to eliminate “hot spots” of infestation, are advised. Using Insect Growth Regulators (IGRs) in the environment can be taken into consideration. All animals in the household should be treated simultaneously.

**Ticks:** Removal and careful disposal of visible ticks and treatment with an approved acaricide.

**Sucking and chewing lice:** Treatment of the animals with insecticides, proven to be effective against lice, and regular washing of bedding and grooming equipment.

**Sand flies/mosquitoes:** Avoidance of “hot-spot” areas and times of day. Regular application of appropriate repellents/insecticides during the risk season.

**Mites:** Treatment with approved acaricides on the animal. Owners should be warned about the potential zoonotic risk of canine and feline sarcoptic mange and cheyletiellosis. Harvest mites may also infest humans.

## Preventing zoonotic infection

Generally important preventive measures for pet owners in terms of ectoparasites.

- Control pet ectoparasite infestations through regular diagnostic testing and/or treatment with appropriate ectoparasiticides, particularly for ticks and parasitic insects.
- Minimise exposure, especially of children, to potentially contaminated environments.
- Practise good personal hygiene.
- Advise people at risk of exposure to zoonotic parasites or any other zoonotic pathogen of the health risks, particularly during pregnancy, or when there is an existing illness or immunosuppression.



Modular Guide 03 Second Edition is adapted from the original ESCCAP Guideline 03 Sixth Edition – March 2018  
© ESCCAP 2009–2020. All rights reserved.

ISBN 978-1-907259-42-5

ESCCAP guidelines are made possible by sponsorship from ALL the major leading pharmaceutical companies.

ESCCAP acknowledges Merial SAS, now part of Boehringer Ingelheim Vetmedica GmbH, for supporting the creation of this guideline.

ESCCAP Secretariat  
Malvern Hills Science Park  
Geraldine Road, Malvern  
WR14 3SZ United Kingdom

Tel: +44 (0) 1684 585135  
[www.esccap.org](http://www.esccap.org)

### Ruby Sponsors:



### Sapphire Sponsors:

Fleas (mainly *Ctenocephalides felis* and *C. canis*) are blood-sucking insects found in the adult stages on dogs and cats as well as other small pets, wild mammals and humans.

Fleas are common parasites and can act as vectors for a number of pathogens and zoonotic infections including *Dipylidium caninum*, *Bartonella* spp. and *Acanthocheilonema reconditum*<sup>1</sup>.

## Distribution

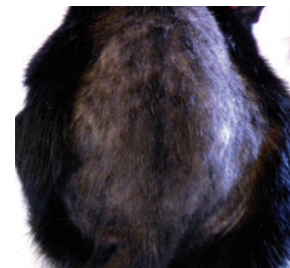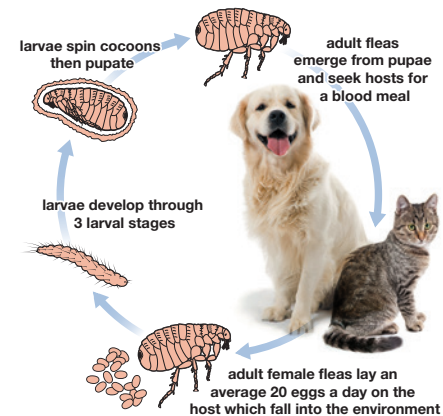
Fleas are common throughout Europe, except in northern Scandinavia.

## Life Cycle

*Ctenocephalides* spp. reproduction shows increased prevalence during warm seasons outdoors and also where optimal (temperature and humidity) indoor conditions exist. Egg production cannot begin until after blood consumption has begun.

Feeding frequently begins within minutes of acquiring a host and female fleas will start laying eggs within 24–48 hours, up to 50 eggs per day. The eggs fall off the animal into the environment and will usually hatch in 1–10 days, depending on temperature and humidity. The larvae feed on flea faeces and they usually hide in dark locations. Moisture in the larval environment is essential for development. Once grown, the larvae pupate in a cocoon that is sticky and becomes coated with debris from the environment. Cocoons are found in soil, in carpets, under furniture and on animal bedding.

Once the pupa has fully developed, the adult flea within the cocoon can be stimulated to emerge from the cocoon upon physical stimulus, carbon dioxide and increasing temperature. Emergence can be delayed by up to 6 months. The brownish, 1–6 mm long and laterally-flattened adult flea seeks a host and requires a daily blood meal to survive. It usually remains on the same host for the remainder of its life, but can also switch hosts, living for up to 160 days.



Flea allergy dermatitis<sup>2</sup>

<sup>1</sup> See ESCCAP Guideline 05: Control of Vector-Borne Diseases in Dogs and Cats.

<sup>2</sup> Photo courtesy of Dermatology Department, Medisch Centrum Voor Dieren Amsterdam.

## Clinical Signs

Flea infestation is highly variable and grooming behaviour in dogs and cats can have a major influence.

The frequency and duration of exposure to infestations, the presence of secondary infections or diseases and possible hypersensitivity are important factors.

Animals that are allergic or develop an immunological reaction to flea saliva can develop flea allergy dermatitis (FAD). Allergic animals may show pruritus, alopecia, broken hairs, papules and erythematous macules with crusts. Moist dermatitis is typically seen in the dorsal lumbar and tail region. Lesions can extend to the thighs and abdomen.

## Diagnosis

In some animals, due to the length and thickness of the coat, low numbers of fleas may be undetected. Regular combing and examination of the coat will demonstrate the presence and profusion of fleas and flea faeces.

Flea bites may cause raised weals on the skin with scratching, licking and biting by the host often leading to hair loss in those areas.

The best method of detection is by combing the coat onto damp white paper or tissue. This may show adult flea stages and flea faeces, which show as black spots surrounded by a red ring of undigested blood, and can assist in a diagnosis of FAD. FAD is one of the most prevalent dermatoses, often associated with intense pruritus and reddening of the skin of the host. FAD can be diagnosed using an intradermal test.

## Treatment

To eliminate existing infestations of adult fleas, pets can be treated with modern, highly effective and long-acting products<sup>2</sup>. Depending on the severity of the infestation and the drug used, treatment may need to be repeated at intervals until the problem is controlled. All animals that inhabit the same home should be included. Environmental treatment is recommended to speed elimination.

The regular use of products that eliminate adult fleas on the animal will progressively contribute to the reduction of immature stages in the environment.

On-animal and environmental products may contain compounds with adulticidal and/or Insect Growth Regulator (IGR) activity. Other measures such as the vacuuming of carpets and washing of pet's bedding material help in reducing flea stages in the environment.

## Control

Flea control is best achieved by a regular tailor-made prevention protocol discussed by the owner and the veterinarian. The protocol will depend on the different scenarios including number of pets in the house, exposure to infestation and immature stages, and whether the animal suffers from FAD. In order for a flea control protocol to be effective the owner must adhere to a long-term protocol and follow treatment recommendations<sup>3</sup>.

<sup>2</sup> See [www.esccap.org](http://www.esccap.org) for therapy tables by country or region.

<sup>3</sup> For more information see: ESCCAP Guideline 03: Control of Ectoparasites in Dogs and Cats.

Ticks are temporary blood feeding parasites that can infest dogs and cats and belong to the genera *Ixodes*, *Rhipicephalus* and *Dermacentor* (family Ixodidae) which are hard ticks.

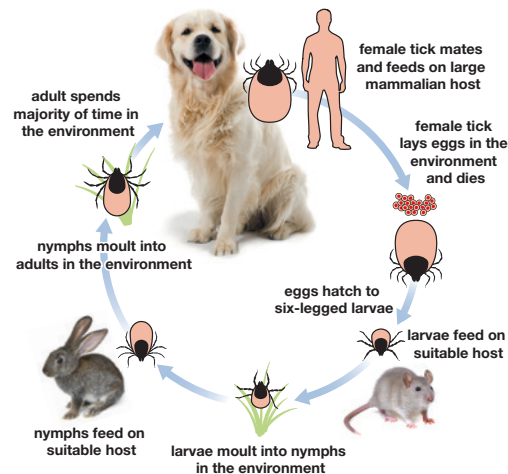
In Europe, the main importance of ticks is their role as vectors of pathogenic agents with salivary fluid as the main route of transmission.

## Tick Borne Diseases (TBDs)

Tick transmitted pathogens can cause a range of TBDs including borreliosis (Lyme Disease), louping-ill virus (Flavivirus), European tick-borne encephalitis (TBE virus)<sup>1</sup>, babesiosis, ehrlichiosis and anaplasmosis.

## Distribution

Ticks are endemic throughout most of Europe and there are more than 12 different species, with distribution varying with biology, climate and geographical location. Generally tick infestation is highly seasonal with peaks in the spring and in the autumn<sup>2</sup>.



<sup>1</sup> For more information on TBDs see ESCCAP Guideline 05: Control of Vector-Borne Diseases in Dogs and Cats.

<sup>2</sup> Current distribution maps and therapy tables by country or region can be found on [www.esccap.org](http://www.esccap.org)

<sup>3</sup> Photo courtesy of Ghent University.



## Life Cycle

European ticks are three-host ticks. Each life cycle stage feeds once on a new host individual after actively seeking or “questing” for their hosts by climbing onto the leaves of small plants such as blades of grass.

In northern Europe the tick *Rhipicephalus sanguineus* (“kennel” or “brown tick”) will not normally survive outdoors but may complete its life cycle inside kennels and houses. *Ixodes ricinus* and *I. canisuga* also occur frequently in dog kennels.

## Clinical Signs

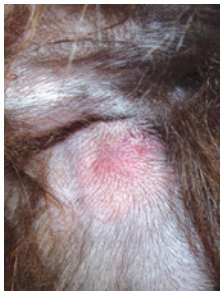Ticks can be found all over the body but the main predilection sites are the non-hairy and thin-skinned areas such as the face, ears, axillae, interdigital, inguinal and perianal regions. The blood-engorged adult females are readily identified on the coat and skin.

## Diagnosis

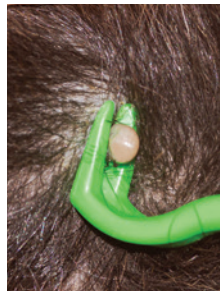Usually made by identifying the ticks on an animal as the blood-engorged female ticks are easy to see. It is more difficult to identify male ticks, unengorged females, nymphal stages and particularly the small larval stages. There may be local skin reactions or micro abscesses due to tick bites. If ticks are not noticed and pathogens have been transmitted, diagnosis may be more difficult as the clinical signs of certain TBDs can be ill-defined.

<sup>2</sup> Current distribution maps and therapy tables by country or region can be found on [www.esccap.org](http://www.esccap.org)

<sup>3</sup> Photo courtesy of Dermatology Department, Medisch Centrum Voor Dieren Amsterdam.



Tick dermatitis<sup>3</sup>



Tick removal tool

## Treatment

Visible ticks should be removed as soon as possible to avoid transmission of pathogens. Use a tick removal tool to ensure complete and effective removal of the whole body including the mouthparts. Do not use oil, alcohol or ether as removal agents and avoid employing pressure on the abdomen of the tick since this may result in an increased TBD infection risk. Careful disposal of the removed ticks is required so that there is no opportunity for them to move to another host or to infect the human. Treat with an approved acaricide because not all the ticks, especially the larval and nymphal stages, may have been detected<sup>2</sup>.

## Control

Avoid or limit access to areas of known high tick density or at times of the year when ticks are known to be most active. Inspect animals for ticks daily after every outdoor activity and remove any ticks found. The use of a suitable acaricide, preferably with a long duration of efficacy and water resistance, prescribed after consultation with a veterinary practitioner, should be followed up by regular examination of non-hairy and thin-skinned areas to reduce the risk of reinfestation. Tick prophylaxis should cover the entire period during which ticks are active.

Dogs and cats travelling to regions with ticks and endemic TBDs should also receive a regular application of acaricidal products, particularly if these TBDs are not endemic in their home country. The use of acaricides with tick repellent activity and/or very quick onset acaricidal activity, can reduce exposure and is considered of advantage for the prevention of TBDs.



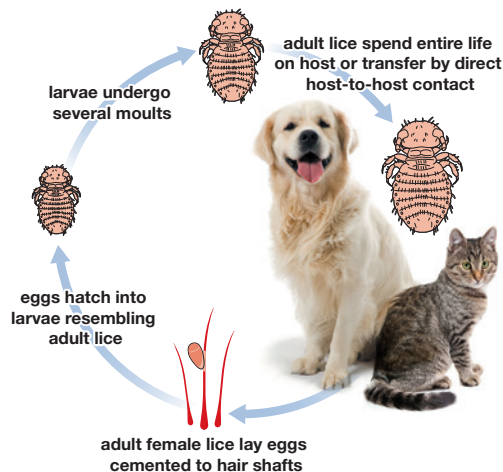
Lice are dorso-ventrally flattened, wingless and highly host specific insects measuring approximately 1–2 mm in length, comprising dog sucking lice (*Linognathus setosus*), dog chewing lice (*Trichodectes canis*) and cat chewing lice (*Felicola subrostratus*).

## Distribution

Dog lice occur sporadically in most of Europe except in Scandinavia where they are more common. Although rare, *Felicola subrostratus* occurs all over Europe and is more common in stray cats.

## Life Cycle

Sucking lice have piercing mouthparts and feed on blood, while chewing lice feed on skin debris. All three species of lice spend their entire life on the host. Adult females lay individual eggs, called nits, and cement these to hair shafts. Transmission occurs by host-to-host contact, which may be direct, or from contact with shared materials such as bedding and grooming equipment. The entire life cycle takes approximately 4–6 weeks.



*Linognathus setosus*<sup>K</sup>



*Trichodectes canis*<sup>A</sup>

<sup>A</sup> Photo courtesy of Department Infectious Diseases and Immunology, Faculty of Veterinary Medicine, Utrecht University.

<sup>K</sup> Photo courtesy of ESCCAP UK.

## Clinical Signs

Louse infestations are generally highly irritating due to the wandering activities of the lice and infested animals can be restless, bad tempered and show excessive itching and rubbing.

Heavy louse infestations are usually characterised by a poorly groomed coat and the presence of nits on the hair, or adult lice within the hair coat. Heavy infestation may cause exfoliative dermatitis with alopecia and crusts due to secondary bacterial infections and in the case of *L. setosus* even anaemia. *Trichodectes canis* can act as a vector for the dog tapeworm *Dipylidium caninum* and *L. setosus* for the canine filarioid *Acanthocheilonema reconditum*.

## Diagnosis

Louse infestation can be diagnosed by close inspection and detection of lice or nits within the hair coat.

*Linognathus setosus* has a typically elongated head and is brown-white in colour with a wide, egg-shaped abdomen. *Trichodectes canis* is yellow-brown in colour and has a typical broad head associated with chewing lice.

*Felicola subrostratus* has an elongated triangular head and is yellow in colour with brown bands.

## Treatment

Infestations can be treated with effective insecticides against lice. There are a number of licensed products with efficacy claims against chewing lice. There are not many licensed treatments against the canine sucking louse except permethrin and fipronil in some Scandinavian countries. However, it is likely that a product effective against chewing lice or fleas will also be effective against sucking lice. All cats or dogs in the same household should be treated<sup>1</sup>.

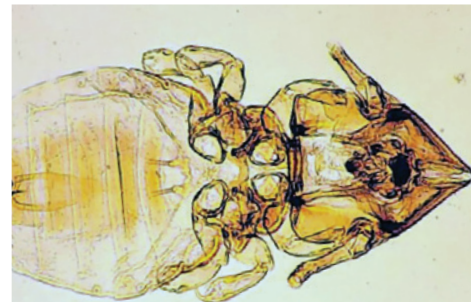## Control

Bedding and grooming equipment should be washed and the environment and any other possible contact areas checked to prevent transmission to other animals<sup>2</sup>.

<sup>1</sup> See [www.esccap.org](http://www.esccap.org) for therapy tables by country or region.

<sup>2</sup> For more information see: ESCCAP Guideline 03: Control of Ectoparasites in Dogs and Cats.

<sup>A</sup> Photo courtesy of Department Infectious Diseases and Immunology, Faculty of Veterinary Medicine, Utrecht University.



*Felicola subrostratus*<sup>A</sup>



Nits within the hair coat<sup>A</sup>



Sand flies (Psychodidae) and mosquitoes (Culicidae) are blood-sucking insects that are important vectors of vector-borne diseases.

**Sand flies.** In Europe only the genus *Phlebotomus* is of veterinary importance and sand flies are important vectors of protozoan parasites of the genus *Leishmania*. Leishmaniosis is a serious disease of dogs which are the main reservoir hosts in Europe. Leishmaniosis is a public health hazard affecting humans and in particular children and immunodeficient adults.

**Mosquitoes** are significant vectors of the pathogenic organisms *Dirofilaria immitis*, (heartworm) and *Dirofilaria repens*. Heartworm is the most pathogenic species whilst *D. repens* is the most important species responsible for zoonotic infections in Europe.

## Distribution

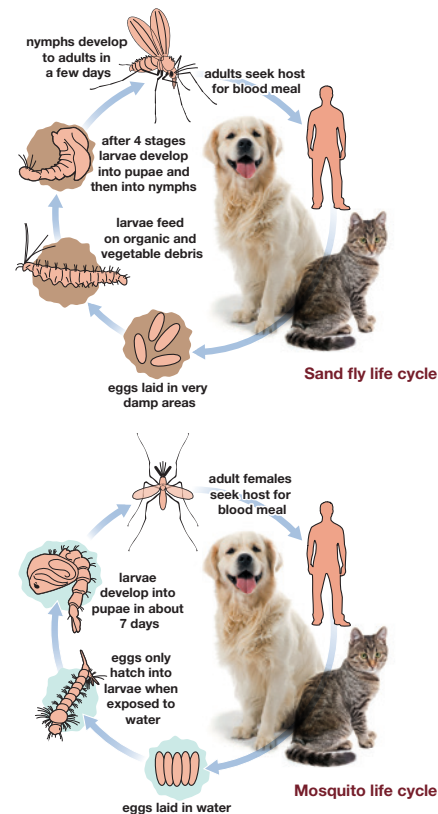
**Sand flies** are well adapted to tropical or subtropical climates and are widespread in the Mediterranean region. The distribution of this insect extends into northern France and localised areas of southern Germany and southern Switzerland.

**Mosquitoes** are distributed worldwide with more than 3,500 species. The most important vectors in Europe are the genera *Culex*, *Aedes* and *Anopheles*. Recently, the Asian tiger mosquito *Aedes albopictus*, which is spreading in Europe, has been shown to be a competent vector for several pathogens including *D. immitis*.

## Life Cycles

**Sand flies** develop in terrestrial habitats and organic matter rather than aquatic environments. The females seek hosts at dawn and after sunset and require blood feeds to produce eggs, which then develop into larvae, which in turn develop through four instars into the adult.

**Mosquitoes** develop in aquatic habitats through four distinct stages. Eggs only hatch when exposed to water. Female mosquitoes begin blood feeding and breeding within a couple of days. The life cycle typically takes up to two weeks, but depending on conditions can range from 4 days to as long as a month.



## Clinical Signs

The typical sites of bites are on exposed skin, mainly the ear pinnae, the nose and the abdomen but bites may also occur on the eyelids, feet and tail. Bites can be painful and give rise to weals.

## Diagnosis

Mosquitoes are easily identified but sand flies are unlikely to be seen as they are very small. Weals on the body of the animal may be the first evidence of bites and these may develop into local skin lesions.

## Treatment and Control

**Sand flies.** Regular use of an insecticide with proven anti-feeding activity is advised throughout the sand fly season<sup>1</sup> (April to November).

Measures to prevent sand fly bites are recommended for endemic areas, and include minimising exposure of dogs to sand flies e.g. not taking pets to leishmaniosis-endemic areas and keeping animals indoors during dawn and after dusk over the whole risk season.

Removing rubbish and organic matter in the vicinity of houses and places where dogs are present can reduce the sand flies' breeding sites.

**Mosquitoes.** Regular application of appropriate repellents designed to prevent mosquito blood-feeding activity. Avoid times and areas where mosquitoes are known to be most active.

Install screens on windows and doors to keep mosquitoes outside. Reduce the number of mosquitoes around the house by emptying standing water on a regular basis<sup>2</sup>.



Sand fly<sup>£</sup>



Mosquito

<sup>1</sup> See [www.esccap.org](http://www.esccap.org) for therapy tables by country or region.

<sup>2</sup> For more information see:  
ESCCAP Guideline 03: Control of Ectoparasites in Dogs and Cats.  
ESCCAP Guideline 05: Control of Vector-Borne Diseases in Dogs and Cats.

<sup>£</sup> Photo courtesy of Dr. Rosa Gálvez, Veterinary Faculty, UCM.

*Demodex* mites of dogs (*Demodex canis*, *D. injai*, *D. cornei*) and cats (*D. cati*, *D. gatoj*, *D. felis*) are host specific.

## Distribution

Demodectic mange mites are common throughout Europe. *Demodex* spp. are viewed as normal commensals. *Demodex gatoj* is considered to be contagious. Increased populations are associated with intercurrent disease or immunosuppression<sup>1</sup>.

## Life Cycle

The life cycles of all *Demodex* spp. are similar and the mites are unable to survive away from their hosts. *Demodex canis* is found in small numbers on many dogs without any clinical signs. The mites spend their entire life in the lumen of hair follicles and, in heavy infestations, invade the sebaceous glands. Newborn puppies typically acquire mites from their mothers through direct contact within the first few days of life, but usually show no clinical signs of infestation. *D. gatoj* lives primarily in the stratum corneum.

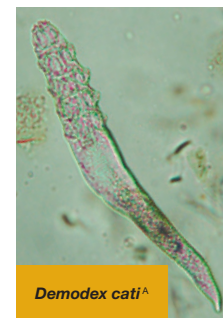
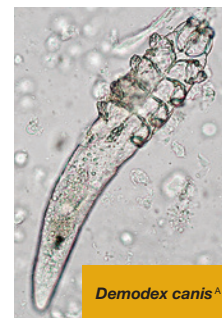
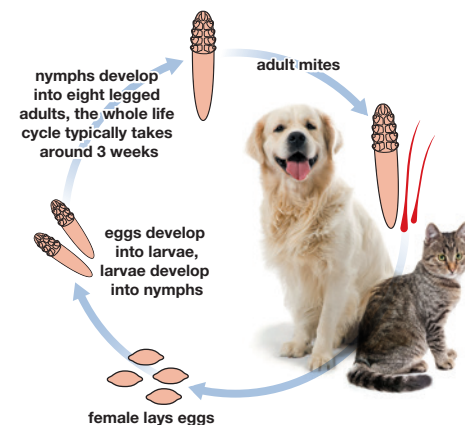
Female mites lay eggs that develop into eight-legged, slender, cigar-shaped adults within approximately 3–4 weeks.

## Clinical Signs

Demodicosis usually occurs as a localised squamous form with non-inflammatory alopecia confined to the eyelids and the periorcular or facial region. Sometimes a generalised pustular form will develop, associated with a disfunction of the cellular immune system and may be considered as a severe, long and potentially life threatening disease. Pruritus is not usually a feature in localised demodicosis, but it is almost always seen in generalised demodicosis with secondary bacterial pyoderma. Juvenile-onset and an adult-onset form of the disease are well differentiated, considering an underlying debilitating disease in the adult-onset or secondary demodicosis. Cats infested with *D. gatoj* are pruritic and may lick or groom affected areas excessively.

<sup>1</sup> For more information see: ESCCAP Guideline 03: Control of Ectoparasites in Dogs and Cats.

<sup>A</sup> Photo courtesy of Department Infectious Diseases and Immunology, Faculty of Veterinary Medicine, Utrecht University.



## Diagnosis

Follicular demodicosis is diagnosed by microscopic examination of deep skin scrapings from small affected areas of alopecia and depends upon identification of the characteristic cigar-shaped, 0.3 mm long mites or their eggs. Take deep scrapings from a fold of skin, apply a drop of liquid paraffin and the skin should be squeezed until follicular content and capillary blood appears. For *D. gato*, a superficial skin scraping from a large area should be collected.

## Treatment

**Dogs.** Localised demodicosis of young animals (<12 months) in most cases will resolve spontaneously within 6–8 weeks without treatment. Since secondary diseases can have a negative impact on healing, general health status should be checked/improved. For generalised demodicosis comprehensive ectoparasitic treatment should include the use of an effective acaricide<sup>2</sup>, evaluation for any underlying disorders, with appropriate treatment when found, and long-term antibiotic therapy when deep pyoderma is present.

It is recommended that ectoparasitic treatment should continue for at least four weeks after the second negative monthly set of skin scrapings.

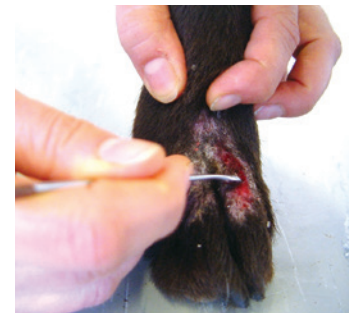**Cats.** The localised form of demodicosis in cats resolves spontaneously in most cases, whereas generalised demodicosis requires treatment. There is no registered product for use in cases of demodicosis in cats. Treatment with macrocyclic lactones, following the protocol recommended for dogs, or lime sulphur dips performed with a 2% solution weekly for 4–6 weeks, have been reported to be effective<sup>2</sup>.

## Control

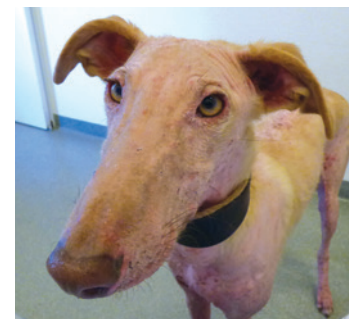The animal's overall health should be evaluated with special consideration being given to conditions affecting the immune system. These include poor husbandry, poor nutrition, internal parasitism and underlying diseases or conditions. To prevent an increase in prevalence of canine demodicosis, it is recommended not to breed from any dog with generalised demodicosis and to neuter affected animals.

<sup>2</sup> See [www.esccap.org](http://www.esccap.org) for therapy tables by country or region.

<sup>B</sup> Photo courtesy of Dermatology Department, Medisch Centrum Voor Dieren Amsterdam.



Taking a skin scraping<sup>B</sup>



Demodicosis<sup>B</sup>

# 3 Modular Guide Series

## 3.5b: Sarcoptic Mange

*Sarcoptes scabiei* mites are only 0.3 mm in size with very short legs. They cause sarcoptic mange in a wide range of mammalian hosts. *Sarcoptes scabiei* var. *canis* is the specific mite of canids.

The mites are largely host-specific with the possibility to temporarily infest other mammals, which explains the zoonotic transmission from dogs to their owners.

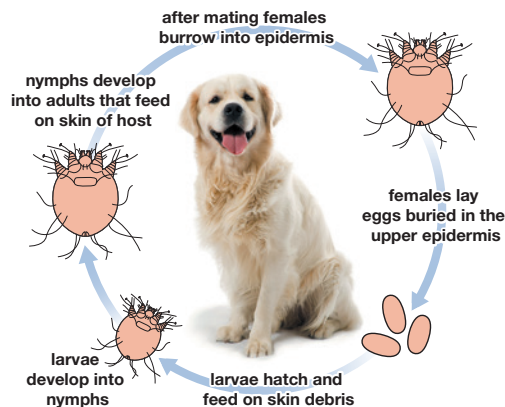
### Distribution

Common throughout Europe *Sarcoptes scabiei* can be highly prevalent in the fox population, particularly in urban areas of central Europe where transmission of mites from the fox population to the dog population has been observed. The infection is rarely seen in cats.

### Life Cycle

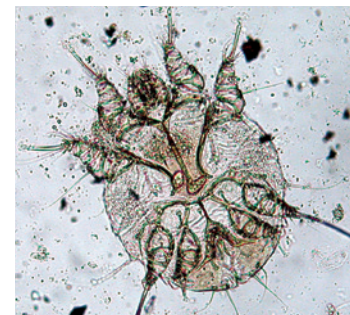
Transmission to new hosts from infested individuals is by direct or indirect contact, most likely by transfer of larvae from the skin surface. The adult mites feed superficially on the skin forming small burrows and feeding pockets. After mating, the female mite burrows more deeply in the upper layers of the epidermis feeding on the fluid and debris resulting from tissue damage.

In the tunnels and side-tunnels thus created it lays eggs for a period of several months. The development from egg to adult stage takes 2–3 weeks. The mites can only survive for 2–3 weeks in the environment.

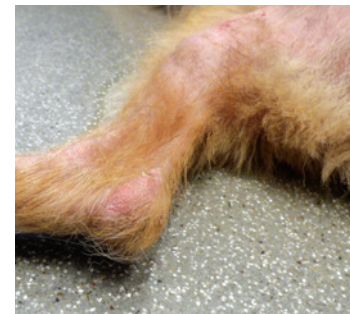

<sup>A</sup> Photo courtesy of Department Infectious Diseases and Immunology, Faculty of Veterinary Medicine, Utrecht University.

<sup>B</sup> Photo courtesy of Dermatology Department, Medisch Centrum Voor Dieren Amsterdam.



*Sarcoptes scabiei* male<sup>A</sup>



Sarcoptic mange<sup>B</sup>



## Clinical Signs

**Dogs.** The pinnae, muzzle, elbows and hocks are predilection sites for *S. scabiei* but in severe infestations, lesions may extend over the entire body. Initial lesions are visible as erythema with papules, which are then followed by papules, pustules, and crusts formation and generalised alopecia and hyperkeratosis on bone prominences. Intense pruritus is characteristic of sarcoptic mange and this can lead to self-inflicted traumatic lesions.

Dogs may begin to scratch before lesions become obvious and it has been suggested that the degree of pruritus may be exacerbated by the development of hypersensitivity to mite allergens or by secondary bacterial colonisation. Without treatment, the disease progresses and lesions spread across the whole skin surface; dogs may become increasingly weak and emaciated.

**Cats.** Although sarcoptic mange is rare in cats, there have been a few confirmed cases. The clinical signs in such cases are reported to be similar to those of notoedric mange.

## Diagnosis

Intense itching that accompanies the disease is the most useful clinical diagnostic feature of canine sarcoptic mange. The ear edge is the most commonly affected site and when rubbed this elicits a scratch reflex in 90% of dogs (positive oto-podal reflex sign). Clinical diagnosis can be confirmed by the examination of several superficial skin scrapings although the sensitivity of this may be as low as 20%. The diagnostic yield is greatly increased by the application of mineral oil to large areas of affected skin before scraping. Commercially available ELISA tests have helped to improve diagnosis. Occasionally humans in contact with affected animals may show a mild dermatitis due to a transient infestation.

## Treatment

Systemic treatments are necessary and most have proved to be effective. It is necessary to eliminate the complete mite burden to prevent the recurrence of disease.

Specific treatments should be preceded or accompanied by suitable washes to soften and remove crusts<sup>1</sup>.

## Control

Sarcoptic mange is highly contagious and affected dogs should be isolated from other animals whilst undergoing treatment. In multi-dog households and kennels it is advisable to isolate positive dogs before including them into the shelter and treat all in-contact animals<sup>2</sup>.

<sup>1</sup> See [www.esccap.org](http://www.esccap.org) for therapy tables by country or region.

<sup>2</sup> For more information see: ESCCAP Guideline 03: Control of Ectoparasites in Dogs and Cats.



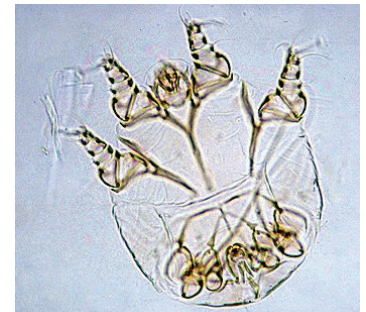
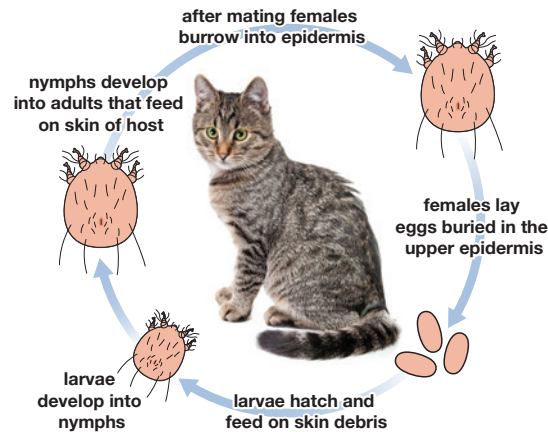
*Notoedres cati* closely resembles *Sarcoptes* both in behaviour and biology but with slight morphological features. Cat notoedric mange is not considered to be zoonotic, but transient dermatitis can occur in humans.

### Distribution

Throughout Europe, but sporadic.

### Life Cycle

The life cycle is similar to that of *Sarcoptes scabiei* but notoedric mites tend to aggregate in small groups forming small nests. The time taken for development from egg to adult stage is 1–3 weeks. Notoedric mange is highly contagious and tends to occur in local outbreaks. Transmission is by close direct or indirect contact, probably by the transfer of larvae or nymphs between hosts. The disease can spread rapidly in groups of cats or among kittens.



*Notoedres cati*<sup>A</sup>



Notoedric mange<sup>F</sup>

<sup>A</sup> Photo courtesy of Department Infectious Diseases and Immunology, Faculty of Veterinary Medicine, Utrecht University.

<sup>F</sup> Photo courtesy of Merial R&D.

## Clinical Signs

Early signs of infestation are local areas of hair loss and erythema on the edges of the ears and the face.

This is followed by greyish-yellow, dry crusting and skin scaling, which progresses to hyperkeratosis with thickening and wrinkling of the facial skin in severe cases.

These clinical signs are accompanied by intense pruritus and scratching, which often results in skin excoriations, secondary bacterial infection and even severe ocular lesions due to self-inflicted traumatic lesions. Cutaneous lesions may spread from the head and neck to other parts of the body when grooming or through simple contact. Untreated animals, mainly kittens, may become severely debilitated and die.

## Diagnosis

Intensely pruritic lesions round the head and ears are characteristic. The small (0.3 mm) round mites with their characteristic concentric “thumb print” dorsal striations are relatively easy to demonstrate microscopically in skin scrapings. Occasionally humans in contact with affected animals may show a mild dermatitis due to a transient infestation.

## Treatment

There are two licensed treatments in the EU (dermal formulations containing moxidectin or eprinomectin). Before application of an appropriate acaricide, animals should be washed with an anti-seborrhoeic and antiseptic lotion to soften and remove skin crusts. Treatment should be repeated until there is a marked clinical improvement and for a minimum of at least 4 weeks<sup>1</sup>.

## Control

It is important to treat all in-contact animals and replace any contaminated bedding<sup>2</sup>.



Notoedric mange can spread rapidly in groups of cats

*Otodectes cynotis* (ear mites) are up to 0.5 mm in size and the most frequent mange mite in carnivores. They are the main cause of otitis and discomfort in dogs, cats and ferrets.

## Distribution

Throughout Europe.

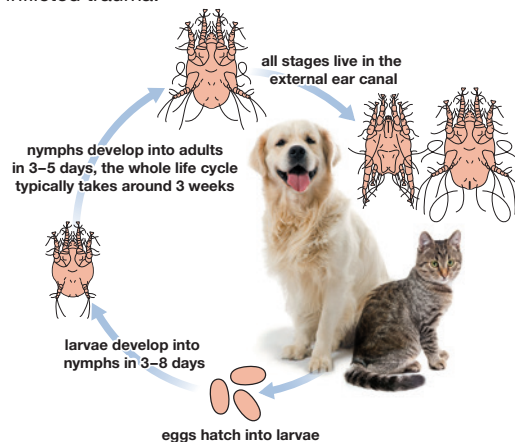
## Life Cycle

The entire life cycle is spent on the host, with transfer from animal to animal probably occurring through close contact. Eggs develop via one larval and two nymphal stages into adults within approximately three weeks.

## Clinical Signs

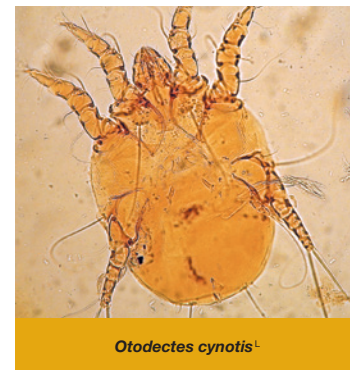
Ear mites can occur in any age group of cats or dogs, but are more common in puppies and kittens and more frequent in cats than dogs. *Otodectes cynotis* are surface dwellers and may be seen using otoscopy as small, motile, white spots in the external ear canal; infestation is typically accompanied by a brown, waxy discharge.

Whilst ear mites may be tolerated without clinical signs in some animals, especially cats, there may be a history of pruritus with ear scratching or rubbing and self-inflicted trauma.



<sup>B</sup> Photo courtesy of Dermatology Department, Medisch Centrum Voor Dieren Amsterdam.

<sup>L</sup> Photo courtesy of John McGarry.



The pinnae and ear canal may be erythematous. Infestation may affect one or both ears. Infrequently the mites may cause dermatitis across the body of the animal.

## Diagnosis

Diagnosis may be reached by seeing the characteristic brown earwax and mites in the external ear canal using an otoscope. Where necessary, samples of wax and debris can be collected from the affected ear canal using a cotton swab or similar. The ear canal may be inflamed and examination and sample collection may be painful. The cotton swab should be rolled onto a microscope slide and examined directly under low magnification. Alternatively, a drop of water, alcohol or liquid paraffin can be added to help to break up the debris. A coverslip can then be applied and the slide examined microscopically.

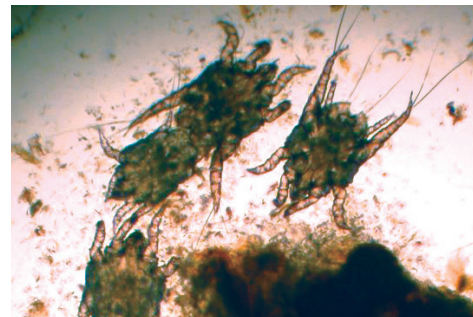
## Treatment

Ear mites may be treated with local administration of ear drops with acaricidal activity or with a systemic spot-on/oral product containing selamectin, moxidectin, sarolaner or fluralaner<sup>1</sup>.

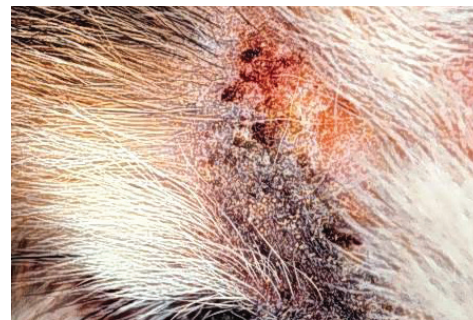Thorough antiseptic cleaning of the ear should be carried out prior to acaricidal treatment. Antibiotic treatment should be employed if the skin surface is colonised by bacteria.

## Control

Depending on the treatment chosen, application may have to be repeated at intervals to eliminate the infestation. In multi-animal households and kennels it is advisable to treat all in-contact animals<sup>2</sup>.



Mites in external ear canal<sup>1</sup>



Mites can cause dermatitis<sup>11</sup>

<sup>1</sup> See [www.esccap.org](http://www.esccap.org) for therapy tables by country or region.

<sup>2</sup> For more information see: ESCCAP Guideline 03: Control of Ectoparasites in Dogs and Cats.

<sup>11</sup> [https://commons.wikimedia.org/wiki/File:Otodectes\\_cynotis.jpg](https://commons.wikimedia.org/wiki/File:Otodectes_cynotis.jpg) by <https://commons.wikimedia.org/wiki/User:Caroldermoid> is licensed under <https://creativecommons.org/licenses/by-sa/3.0/deed.en> / colour enhanced and cropped from original.

<sup>11</sup> Photo courtesy of Professor Marcelo de Campos Pereira, Department of Parasitology, University of São Paulo.

*Cheyletiella* spp. mites (fur mites) can infest dogs, cats and rabbits. Fur mites can also be transmitted to humans, causing a localised dermatitis.

Dogs and cats are infested with distinct species: *Cheyletiella yasguri* infesting dogs and *Cheyletiella blakei* infesting cats. However, these species may not be strictly host-specific.

## Distribution

Throughout Europe.

## Life Cycle

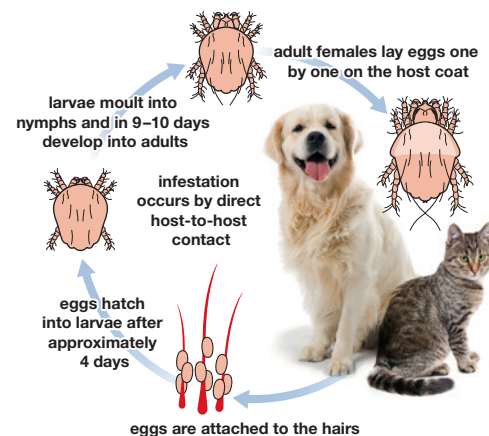
The entire development takes approximately three weeks on the host, although nymphs can survive at cool temperatures for up to a month without the host, while female mites can survive for up to ten days in the environment. Transfer from host-to-host occurs readily and rapidly between animals in close contact. Cheyletiellosis is common in kennels, and young and weak animals seem more susceptible.

## Clinical Signs

The mites may be well tolerated in some animals with excessive scaling being the only clinical sign, while in others pruritus in variable degrees may be present. The large (0.5 mm) mites may be seen as white spots moving amongst the skin scales ("walking dandruff").

**Dogs.** Often found in young animals in good physical condition and may be more prevalent in short-haired breeds of dog. Very little skin reaction or pruritus but in rare, severe cases, affected areas may show erythematous and crusting lesions involving much of the body surface.

**Cats.** Gives rise to mild dermatosis with moderate skin lesions and pruritus. Affected areas may appear as miliary dermatitis with a dorsal clinical pattern.



Adult *Cheyletiella* mite<sup>©</sup>

© Photo courtesy of Robert Armstrong/Merck.



## Diagnosis

For microscopic examination, brush or comb the animal's coat and collect the debris in a petri dish. Alternatively, apply a transparent adhesive tape strip to the affected area and then apply the strip to a microscope slide with 1–2 drops of mineral oil. It is also possible to lightly trim the coat, carry out a superficial skin scrape and collect the debris in a suitable container.

The debris may be examined using a stereomicroscope or magnifying glass and mites may be seen walking amongst the debris. *Cheyletiella* spp. eggs may be seen attached to hairs. Since infected dogs or cats may groom excessively, eggs that have passed through the intestinal tract are sometimes detected on faecal examination.

<sup>1</sup> See [www.esccap.org](http://www.esccap.org) for therapy tables by country or region.

<sup>2</sup> For more information see: ESCCAP Guideline 03: Control of Ectoparasites in Dogs and Cats.

<sup>3</sup> Photo courtesy of Dermatology Department, Medisch Centrum Voor Dieren Amsterdam.

## Treatment

Infested animals can be treated with a suitable topical acaricide, but there is a general lack of licensed preparations.

Studies have shown that topical applications of selamectin, eprinomectin, moxidectin or fipronil and systemic administration of milbemycin oxime are highly effective against *Cheyletiella*.

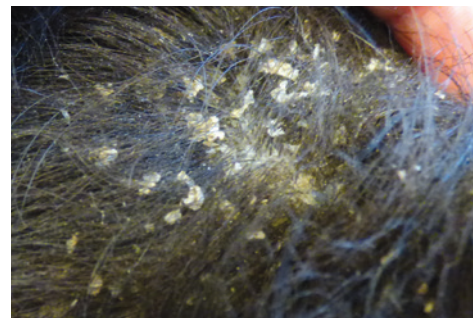Depending on the duration of activity of any compound, treatment may need to be repeated to eliminate the infestation<sup>1</sup>.

## Control

Treatment of in-contact animals, particularly of the same species, is recommended even if they are showing no signs of infestation. Cleaning of the environment, including washing bedding, vacuum cleaning and acaricide application help eliminate any mites in the environment. Owners may be transiently infested and develop a skin rash after contact with infested animals<sup>2</sup>. Clinical signs of the owner will disappear when the animal is treated.



Animals may groom excessively



Walking dandruff<sup>3</sup>



Harvest mites (chigger mites) are responsible for the condition known as trombiculosis. The two responsible species in dogs and cats are: *Neotrombicula* (syn. *Trombicula*) *autumnalis* and *Straelensia cynotis*.

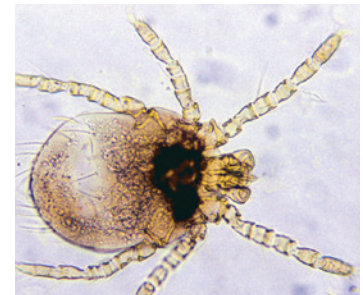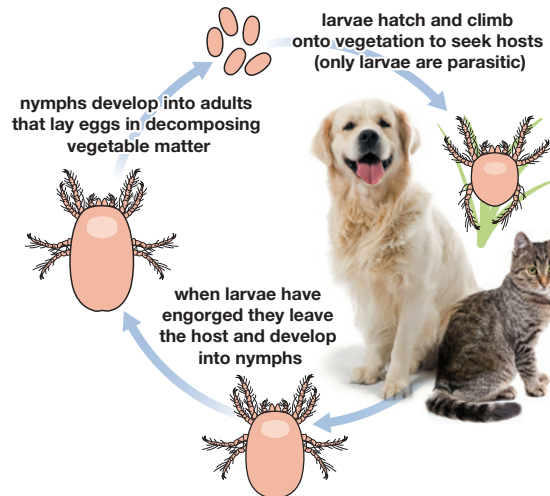
## Distribution

*Trombicula* is found throughout Europe. *Straelensiosis* has been observed in southern France, northern Portugal and Spain.

## Life Cycle

The adult mites lay their eggs in decomposing vegetable matter and in a few days the eggs hatch into larvae; these are of a characteristic orange-grey colour about 0.2–0.3 mm in length. Only the larvae are parasitic. In temperate climates, larvae become active in dry, sunny conditions at temperatures exceeding +16°C. This often occurs between late summer and autumn; thus the term “harvest mite”.

The larvae climb onto the vegetation where they wait for passing hosts. There is no transfer from animal to animal and after attaching themselves to their hosts they feed for several (5–7) days on enzymatically liquefied tissue, epithelial secretions or blood.



Harvest mite larval stage<sup>A</sup>

Thereafter, they detach and continue their development as free-living stages on the ground. Also humans or other animals can get infested.

The complete life cycle may take 50–70 days or more. Harvest mites are resistant to adverse climatic conditions and female mites can live for more than 1 year. In areas with a temperate climate there is usually one generation per year, but in warmer areas they may complete more than one cycle per year.

<sup>A</sup> Photo courtesy of Department Infectious Diseases and Immunology, Faculty of Veterinary Medicine, Utrecht University.

## Clinical Signs

Cutaneous lesions are usually found in ground–skin contact areas like the head, ears, legs, feet and ventral areas. The lesions are highly irritating and pruritic and may develop to a papulo-crusting generalised dermatitis. Macroscopically the mites are very peculiar due to the bright orange colour of the larval mites. Severe hypersensitivity reactions have been observed in cases of repeated infestation.

## Diagnosis

Gross observation of the lesions, together with the time of year and the history of affected dogs and cats having been in the countryside, are often sufficient for a diagnosis.

The larval mites can also be seen fairly easily without magnification. Skin scrapings and direct impressions, in an attempt to find *Straelensia* parasites are consistently unsuccessful. Histological examination of the nodules may reveal the presence of dilated hair follicles containing a larval mite.

## Treatment

Fipronil (in both dogs and cats), synthetic pyrethroids (exclusively in dogs) and selamectin can be successfully used to kill harvest mites.

Topical spray treatments may be repeated every 3–5 days in order to prevent reinfestation. Frequent spraying of the commonly affected areas such as paws and ventral abdomen may be more effective than less frequently applied spot-on preparations<sup>1</sup>.

Palliative treatment using e.g. antipruritics may reduce the local skin irritation.

## Control

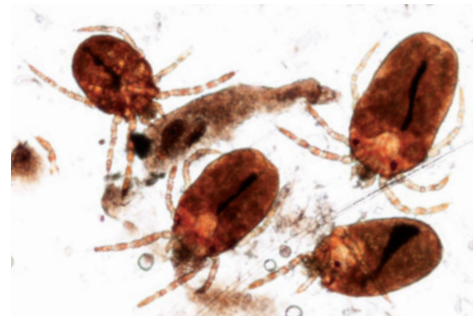
Control of trombiculosis is difficult due to the fact that reinfestations are frequent in animals exposed to these mites<sup>2</sup>.

<sup>1</sup> See [www.esccap.org](http://www.esccap.org) for therapy tables by country or region.

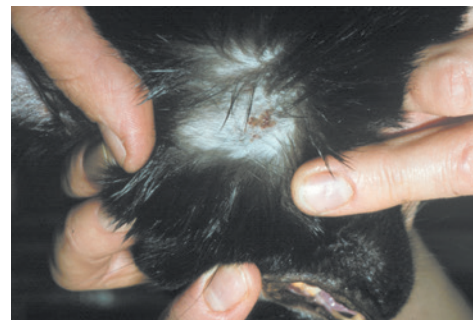<sup>2</sup> For more information see: ESCCAP Guideline 03: Control of Ectoparasites in Dogs and Cats.

<sup>B</sup> Photo courtesy of Dermatology Department, Medisch Centrum Voor Dieren Amsterdam.

<sup>G</sup> Photo courtesy ENVA, L'Ecole Nationale Vétérinaire d'Alfort.



Harvest mites<sup>B</sup>



Dermatitis caused by harvest mites<sup>G</sup>

Canine nasal mites, *Pneumonyssoides (Pneumonyssus) caninum*, are permanent parasites of the nasal cavities and paranasal sinuses, especially the ethmoid<sup>1</sup>.

### Distribution

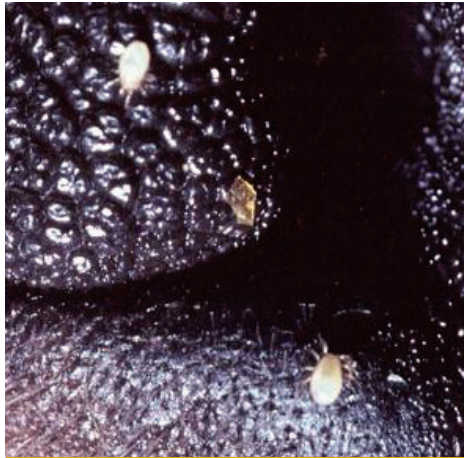Very rare throughout Europe but particularly prevalent in Scandinavia.

### Life Cycle

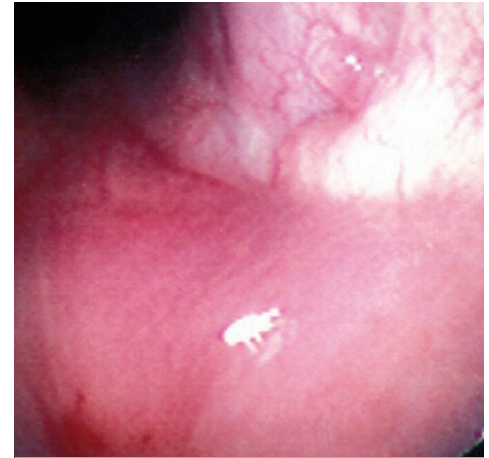The life cycle of this infrequently occurring parasite is still not completely known. The adults are visible macroscopically and the females reach a length of 1–1.5 mm and a width of 0.6–0.9 mm.

The most likely mode of transmission is by direct contact between dogs, considering the active movements of the larvae which can be detected in the nostrils of affected animals.

Indirect transmission in cages and kennels and by fomites such as bedding cannot be ruled out since these parasites can survive for up to 20 days outside the host.



Canine nasal mites in nostril of dog<sup>1</sup>



Endoscopic view of nasal mites<sup>11</sup>

<sup>1</sup> For more information see: ESCCAP Guideline 03: Control of Ectoparasites in Dogs and Cats.

<sup>11</sup> From The Merck Veterinary Manual, 10th edition, online version. Susan E. Aiello, ed. Copyright © 2015 by Merck & Co., Inc., Whitehouse Station, NJ. All rights reserved. Used with permission, courtesy of Dr. Steven L. Marks, NC State College of Veterinary Medicine, and the Merck Veterinary Manual. Available at: [www.MerckManuals.com](http://www.MerckManuals.com) Accessed November 11, 2015.

<sup>12</sup> Photo courtesy of [www.vetbook.org](http://www.vetbook.org) - [www.vetbook.org/wiki/dog/index.php/Pneumonyssoides\\_spp](http://www.vetbook.org/wiki/dog/index.php/Pneumonyssoides_spp)

## Clinical Signs

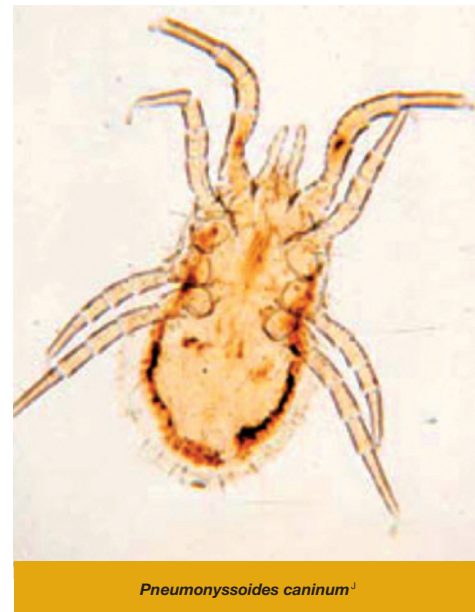
The clinical signs described vary depending on the parasite burden, from an absence of any signs to severe cases of nasal discharge, sneezing, fatigue, and head-shaking. In very severe cases purulent rhinitis and sinusitis may occur.

## Diagnosis

The inaccessible localisation makes in vivo diagnosis difficult and except in rare cases the presence of nasal mites is detected post-mortem. Retrograde nasal flushing and nasal endoscopy may help to find the mites.

## Treatment

Different ectoparasiticides have been tested in the treatment of this parasitosis with variable results. Macrocytic lactones such as milbemycin (licensed for this indication in some countries), selamectin and moxidectin appear to be the most effective. Three treatments at an interval of 7–14 days are recommended<sup>2</sup>.



*Pneumonyssoides caninum*<sup>1</sup>

<sup>2</sup> See [www.esccap.org](http://www.esccap.org) for therapy tables by country or region.

<sup>1</sup> Photo courtesy of [www.vetbook.org](http://www.vetbook.org) - [www.vetbook.org/wiki/dog/index.php/Pneumonyssoides\\_spp](http://www.vetbook.org/wiki/dog/index.php/Pneumonyssoides_spp)